

# Surgical Pathology Conference



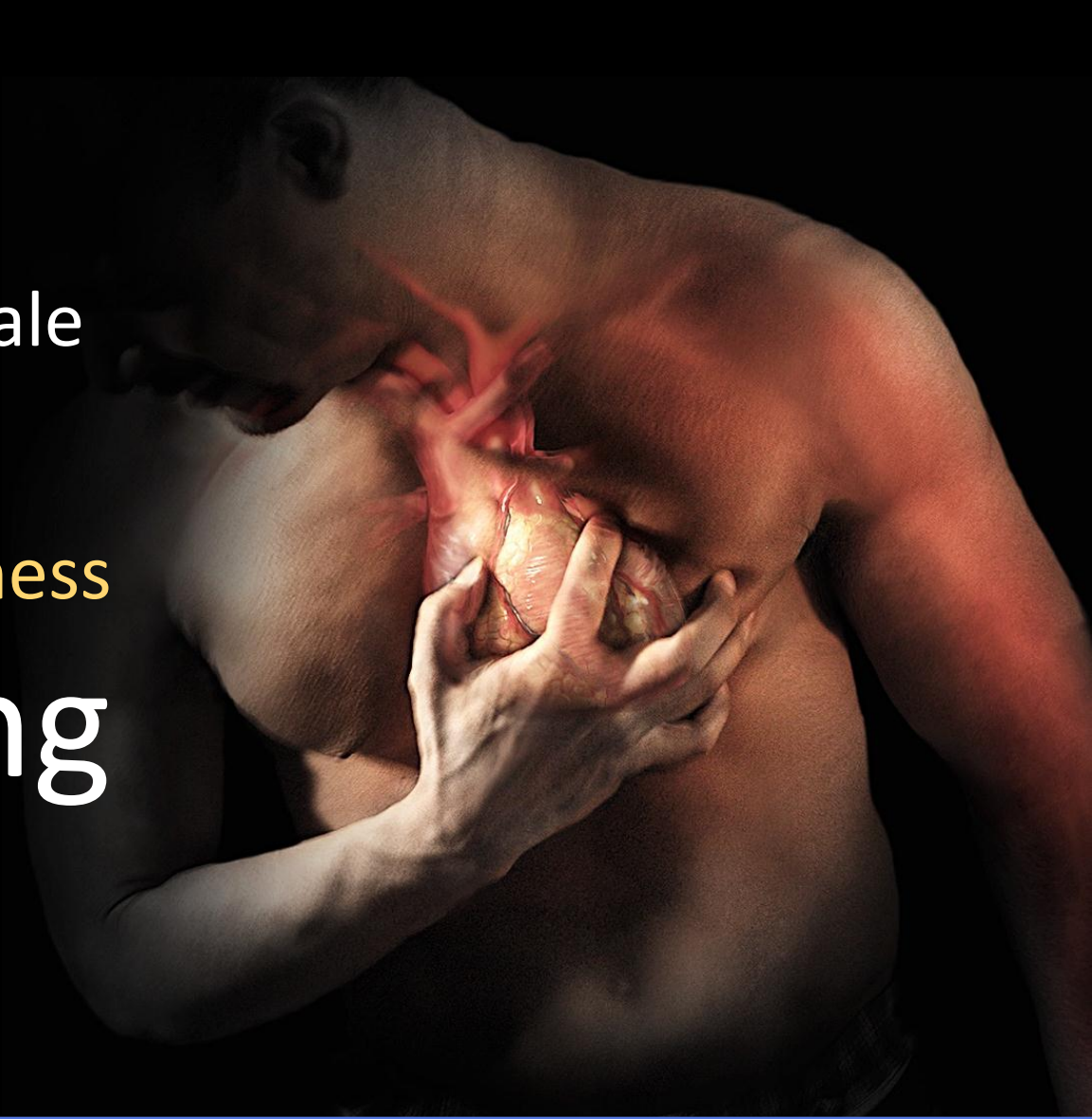
104-12-26

Sheng-han Tsai, MD

Department of Urology  
Division of Minimal Invasive Surgery  
Cheng Hsin General Hospital, Taipei, Taiwan

46 year-old male

Palpitation, dizziness  
on voiding





Health exam  
VGHTPE

Jan, 2014

July, 2015

Oct, 2015

Symptoms  
attack

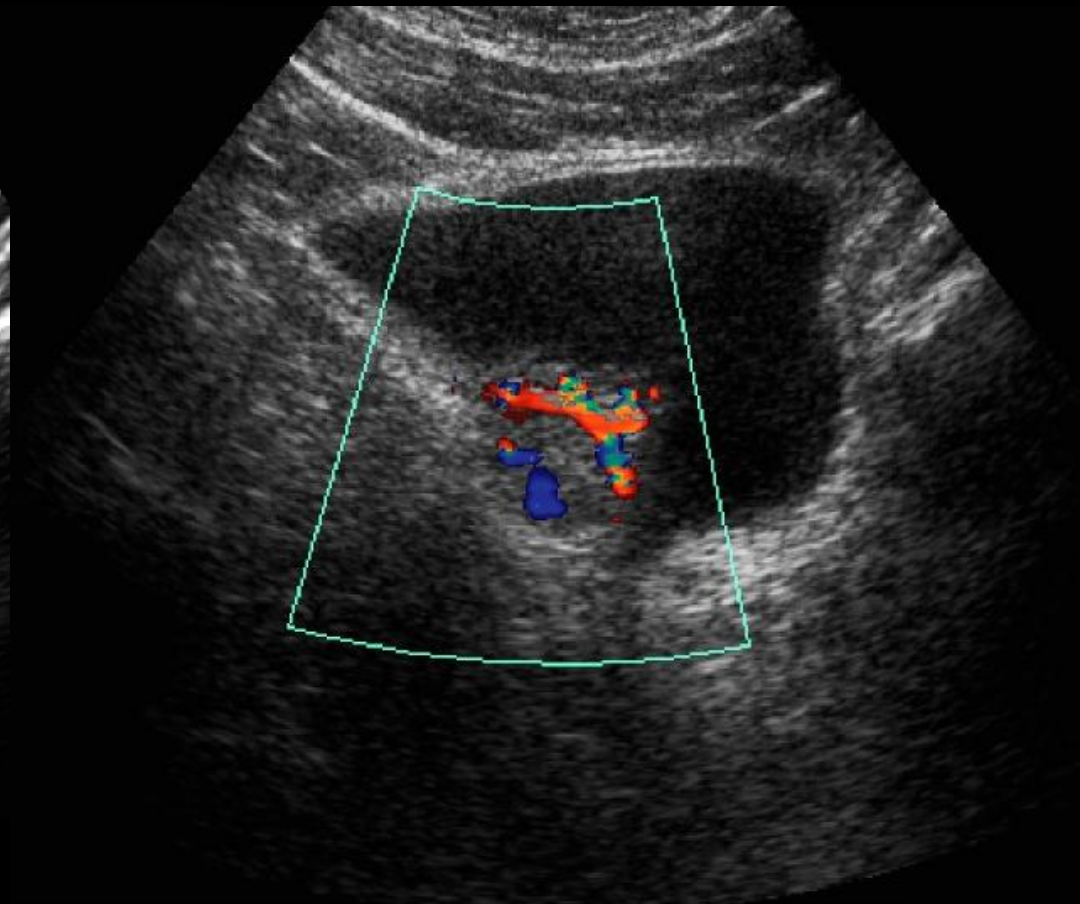
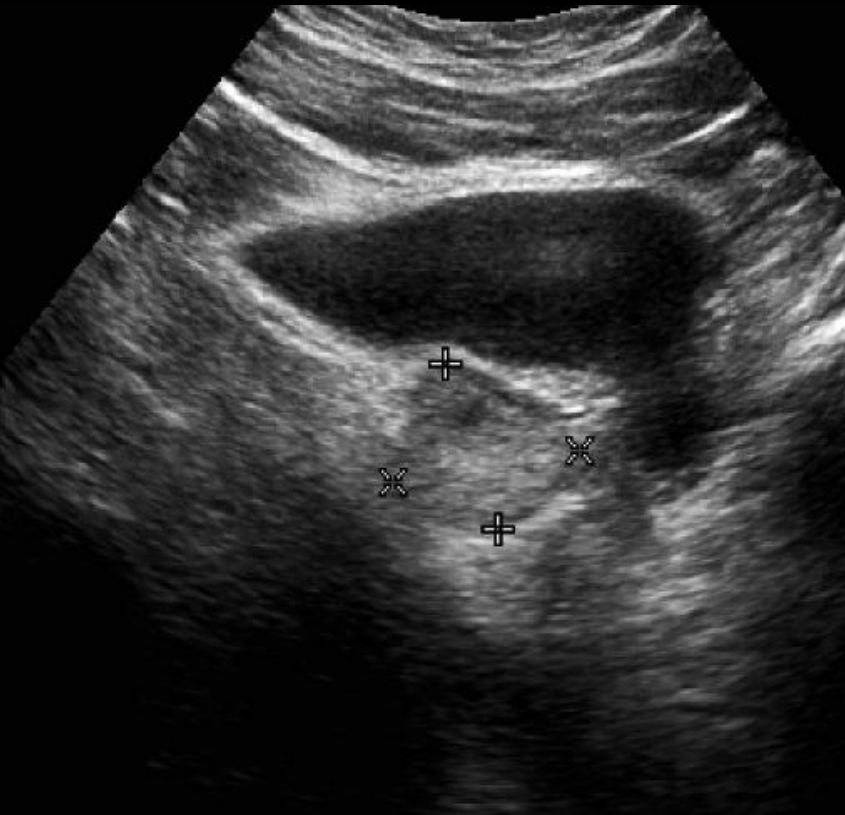

GU OPD  
evaluation





# Intramural Bladder Tumor





## Intramural Bladder Tumor

### Plasma Catecholamine

Epinephrine	56 pg/ml
-------------	----------

Norepinephrine	804.6 pg/ml
----------------	-------------

### Urinalysis

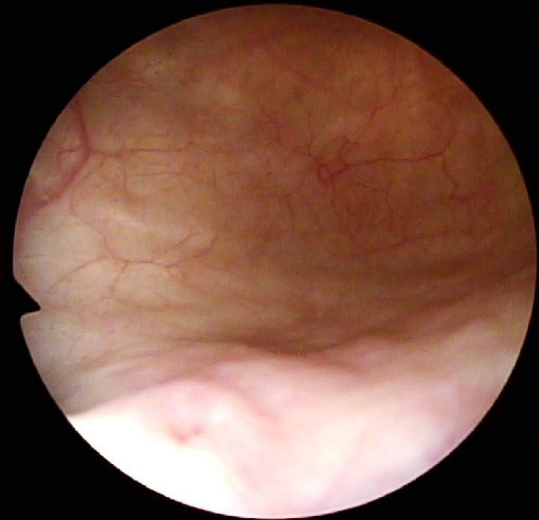
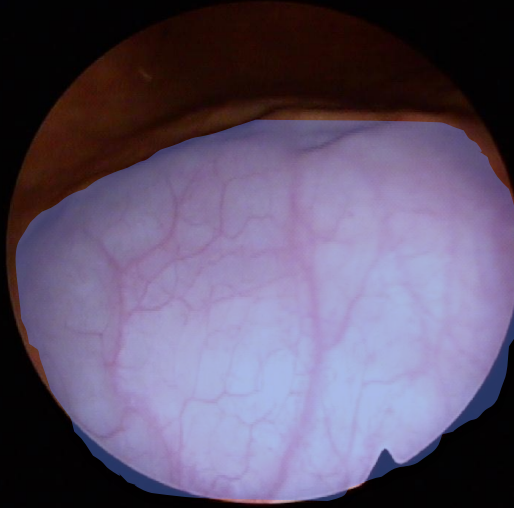
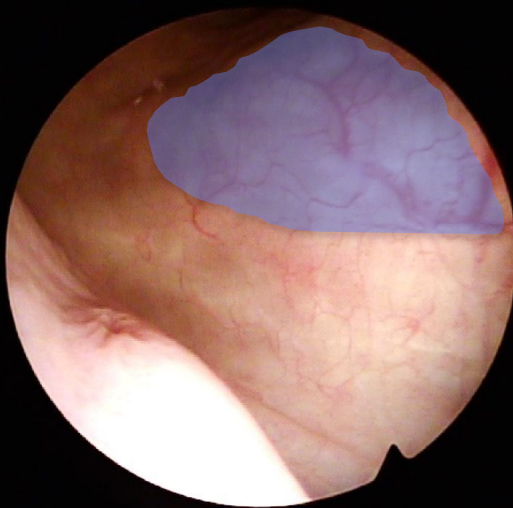
WBC	0 /HPF
-----	--------

RBC	0 /HPF
-----	--------

---

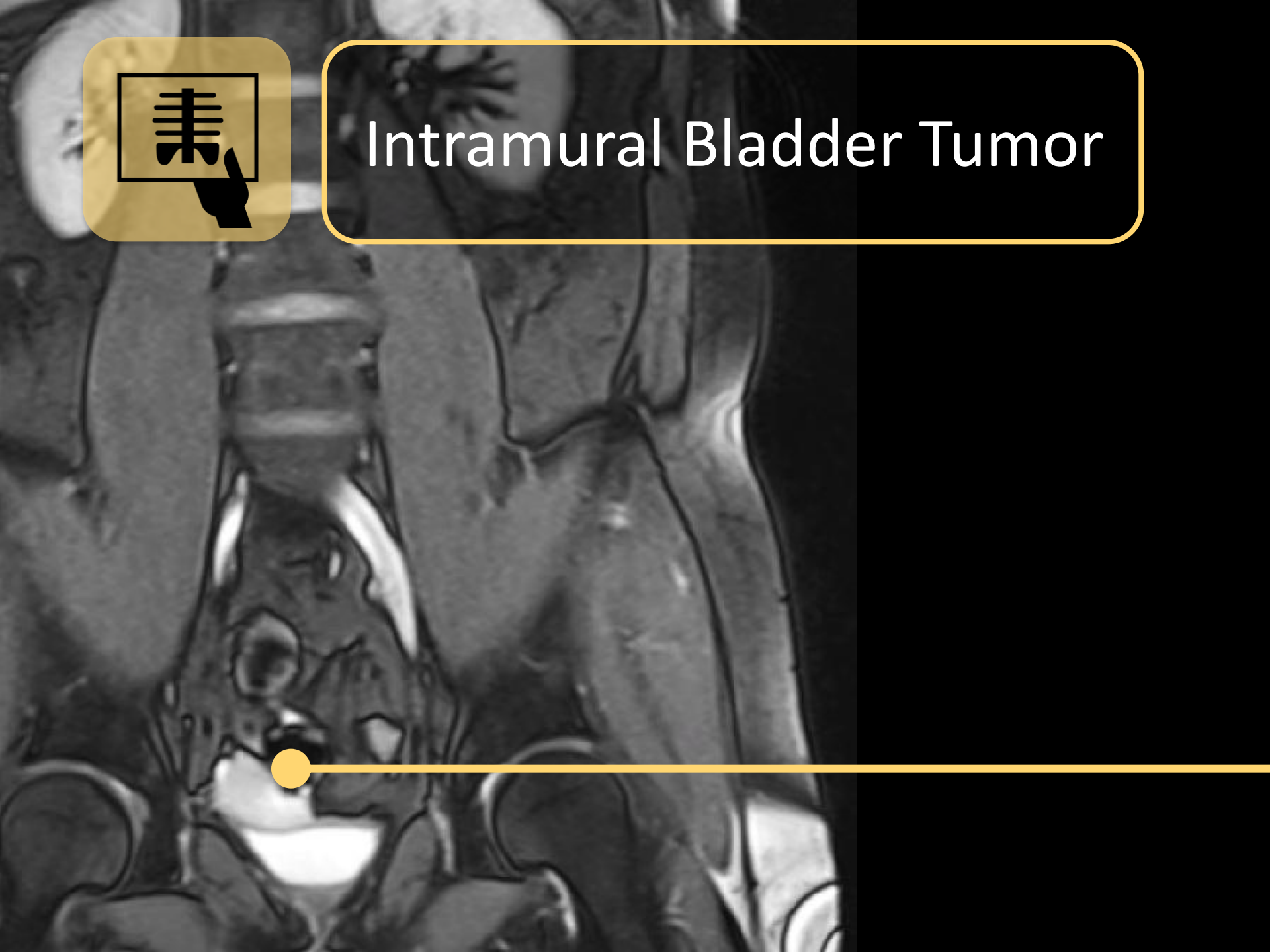


# Intramural Bladder Tumor





# Intramural Bladder Tumor





# Intramural Bladder Tumor

## Impression

Extra-adrenal Paraganglioma

Leiomyoma / sarcoma

## Pre-surgical Medication

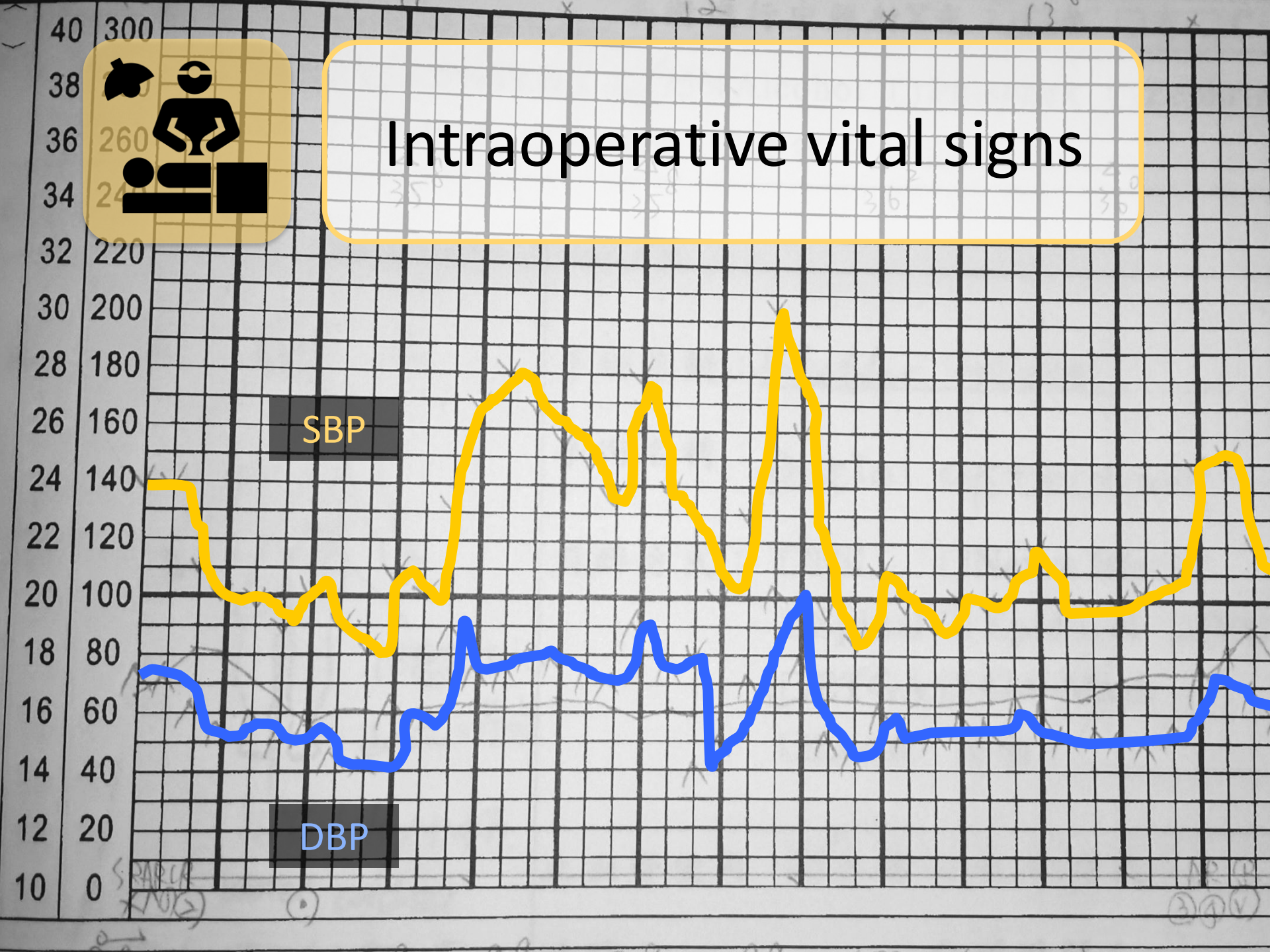
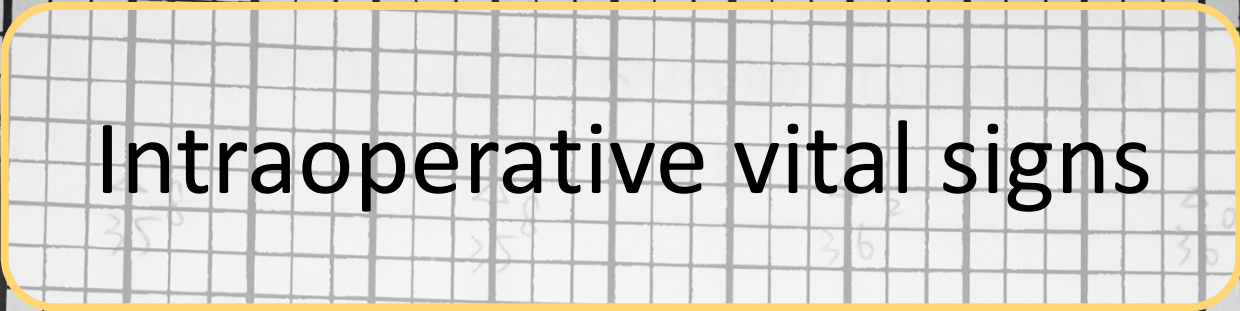
Doxazosin                      4mg    QD

---



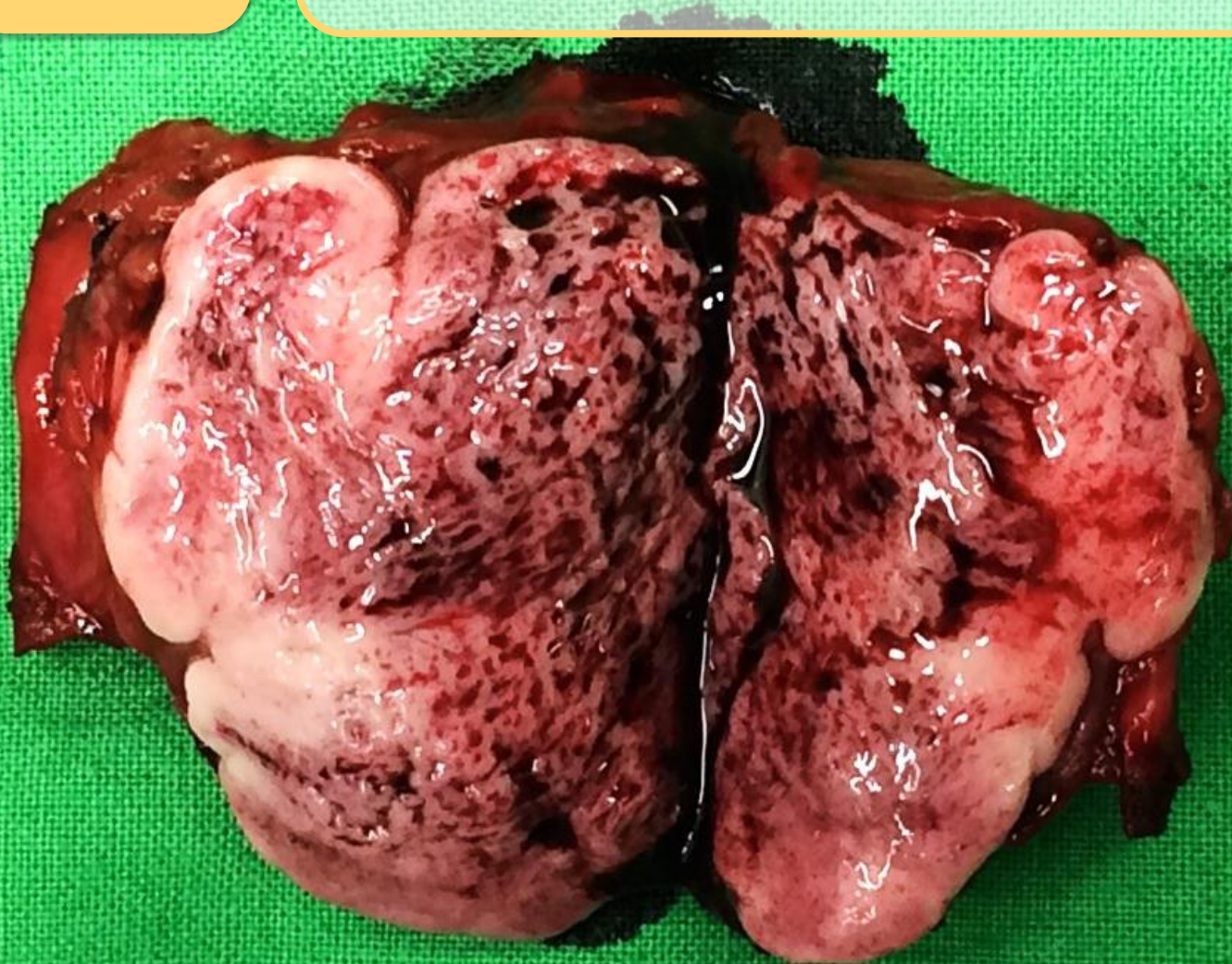
# Partial Cystectomy







## Gross picture of tumor

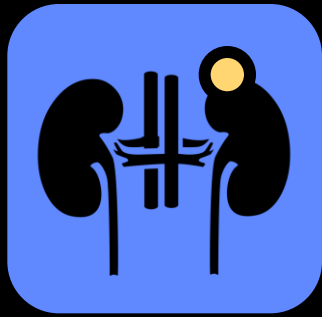

1 cm

A white double-headed arrow indicating a scale of 1 cm.



Pathology page



# Mini-review

## 2004 WHO Pheochromocytoma : Intra-adrenal paraganglioma

### Biochemical

- Urine catecholamine
- Plasma catecholamine
- Urine metanephrine

### Radiological

- CT
- MRI
- $^{123}\text{I}$  MIBG scintigraphy
- PET



# Management

Treatment of choice: **surgery**

Pre-surgical medication: **AB, BB, CCB, ARB**

Malignancy: **3-36 %**

Treatment option :  
**Debulking, RT, RFA, C/T, I<sup>131</sup> MIBG therapy**

RESEARCH ARTICLE

Open Access

# Pheochromocytoma of the urinary bladder: a systematic review of the contemporary literature

Jonathan A Beilan<sup>1,2</sup>, Adrienne Lawton<sup>3</sup>, Julio Hajdenberg<sup>4</sup> and Charles J Rosser<sup>1,2\*</sup>

## Pubmed search

- Paraganglioma, pheochromocytoma, bladder
- English
- 19+ yrs old
- 1980 - 2012



80



106



---

Male / Female : 55 / 51



Mean age : 43.3 yrs

HTN (54.7%)

Headache (48.1%)

Hematuria ( 47.2%)

Syncope/palpitation (43.4%)



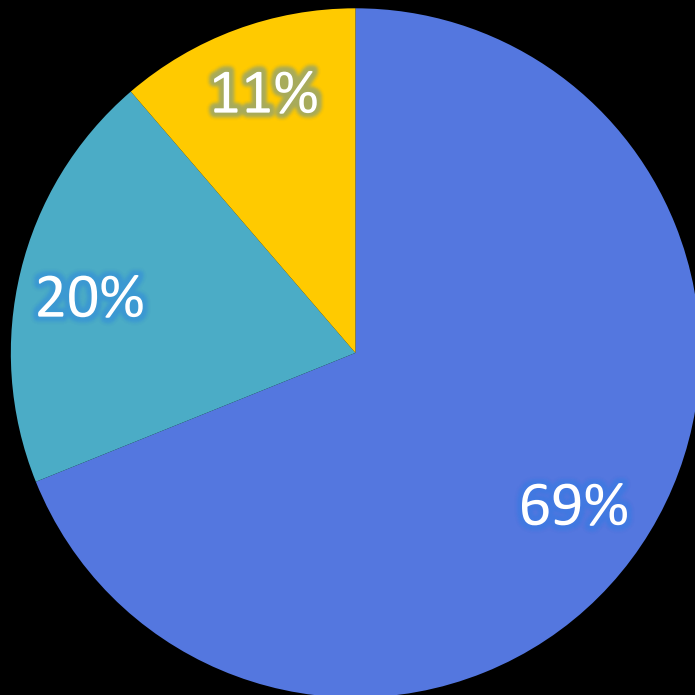
Mean size : 3.9 cm

Catecholamine ↑ 61.3%





# Surgical treatment



- Partial cystectomy
- TURBT
- Radical cystectomy

Recurrence

14.2%

Mets : 9.4%

Death : 3.8%



# Bladder Paraganglioma

Micturition attack

Surgical treatment

Long term follow-up

---



# Bladder Paraganglioma

Micturition attack  
Surgical treatment  
Long term follow-up

Sheng-han Tsai, MD

Department of Urology  
Division of Minimal Invasive Surgery  
Cheng Hsin General Hospital, Taipei, Taiwan

