

# 振興醫療財團法人振興醫院

題目：血尿

主講 泌尿外科

王曉暹主任

# 血尿

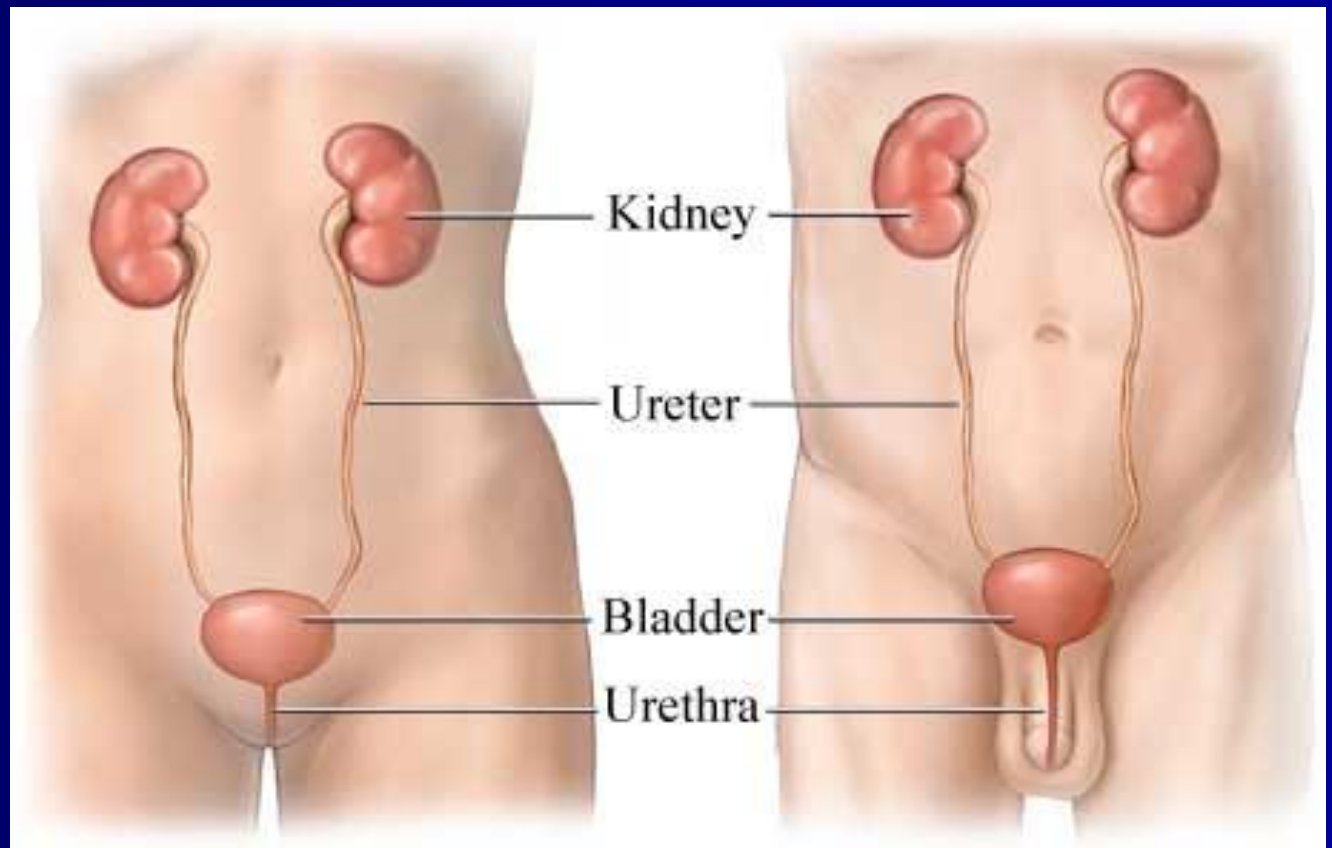
➤ 量

➤ 質

➤ 症狀

# Introduction (I)

- 泌尿系統是人體水路的重要疏通管道，尿液必須經由腎臟通過輸尿管、膀胱、尿道而被排出體外。



# 量

- 顯微鏡下可見
- 肉眼可見
- 假性血尿

# 質

- 全血尿
- 終端血尿
- 起始血尿
- 婦科出血

# 症狀

- 腰痛
- 排尿疼痛
- 發燒，發冷
- 頻尿，膀胱疼痛
- 無症狀

# 原因

- 發炎
- 結石
- 癌症
- 受傷
- 內科疾病
- 無原因

# 發炎

- 尿道炎
- 膀胱炎
- 攝護腺炎
- 腎盂腎炎



# 結石

- 腎結石
- 輸尿管結石
- 膀胱結石

# 泌尿道癌

- 腎實質癌
- 腎盂癌
- 輸尿管癌
- 膀胱癌
- 攝護腺癌

# 受傷

- 撞擊
- 騎車
- 手術後

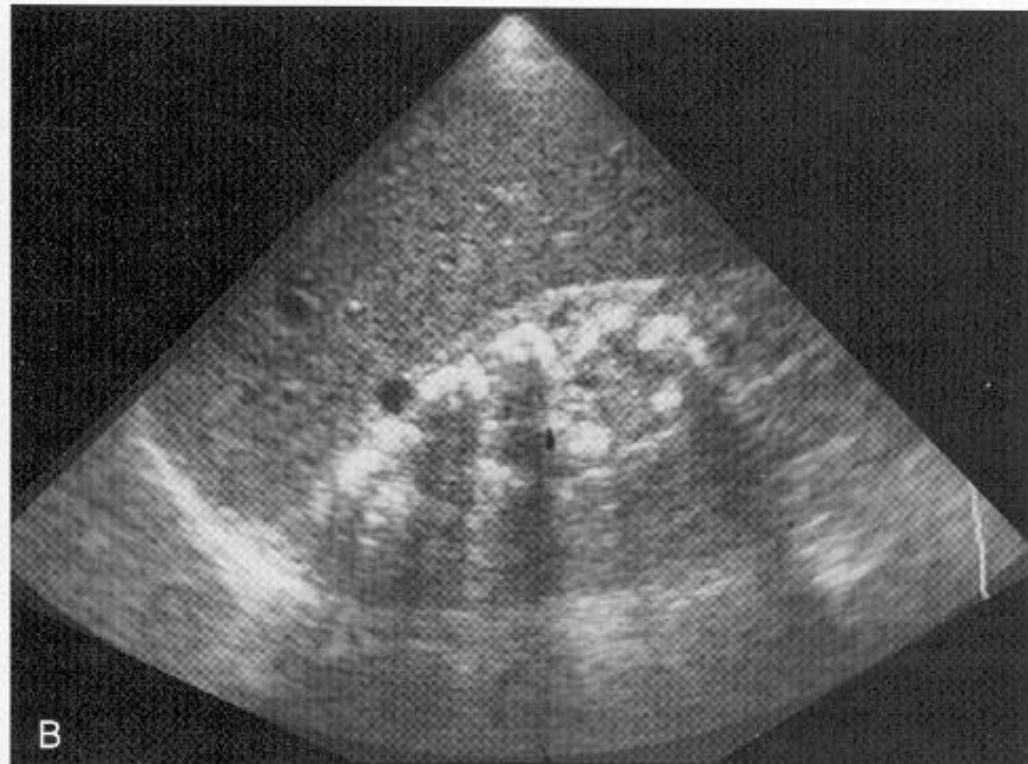
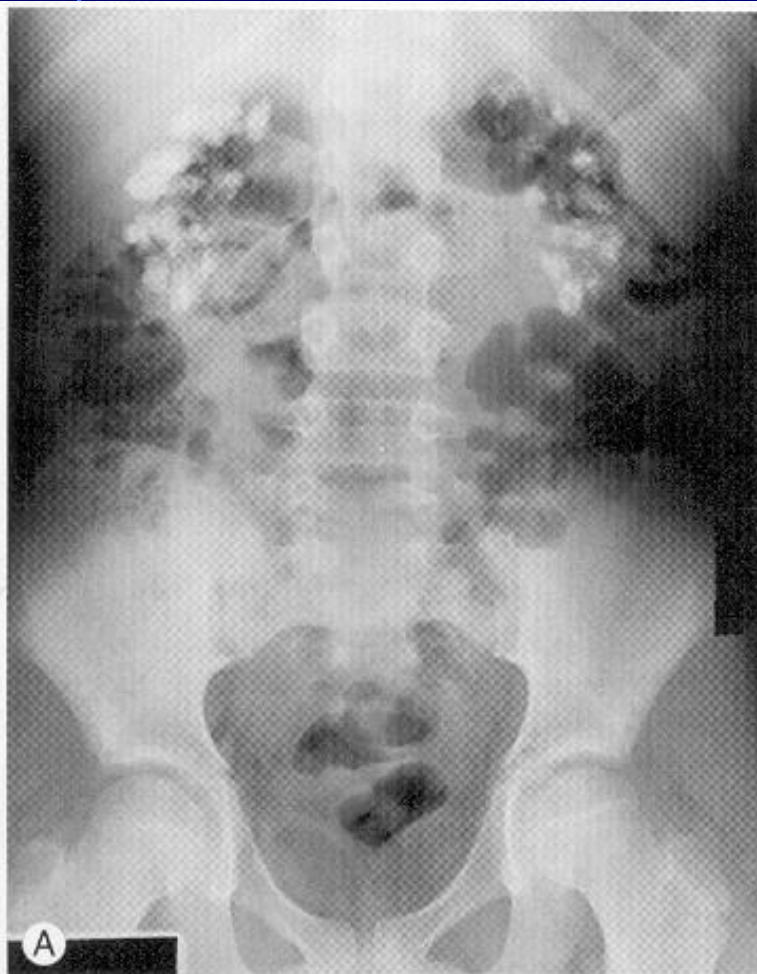
# 內科原因

- 腎臟疾病
- 血液科疾病
- 化學治療
- 放射治療

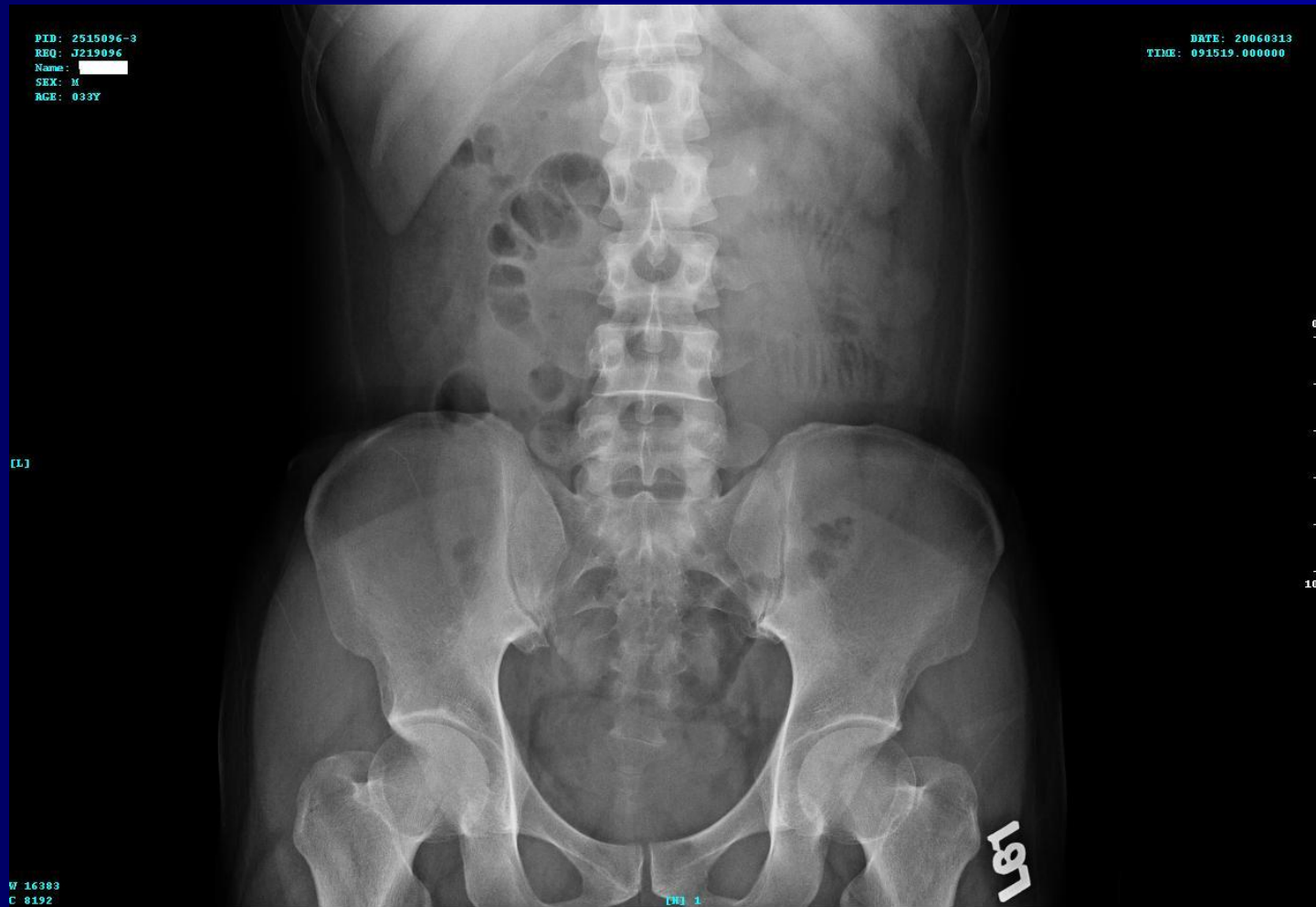
# 檢查

- 尿液檢查
- 超音波
- 泌尿道顯影劑檢查
- 電腦斷層，核磁共振
- 膀胱鏡

# Plain radiographic (A) and ultrasonic (B) presentations of nephrocalcinosis



# Intravenous pyelogram A



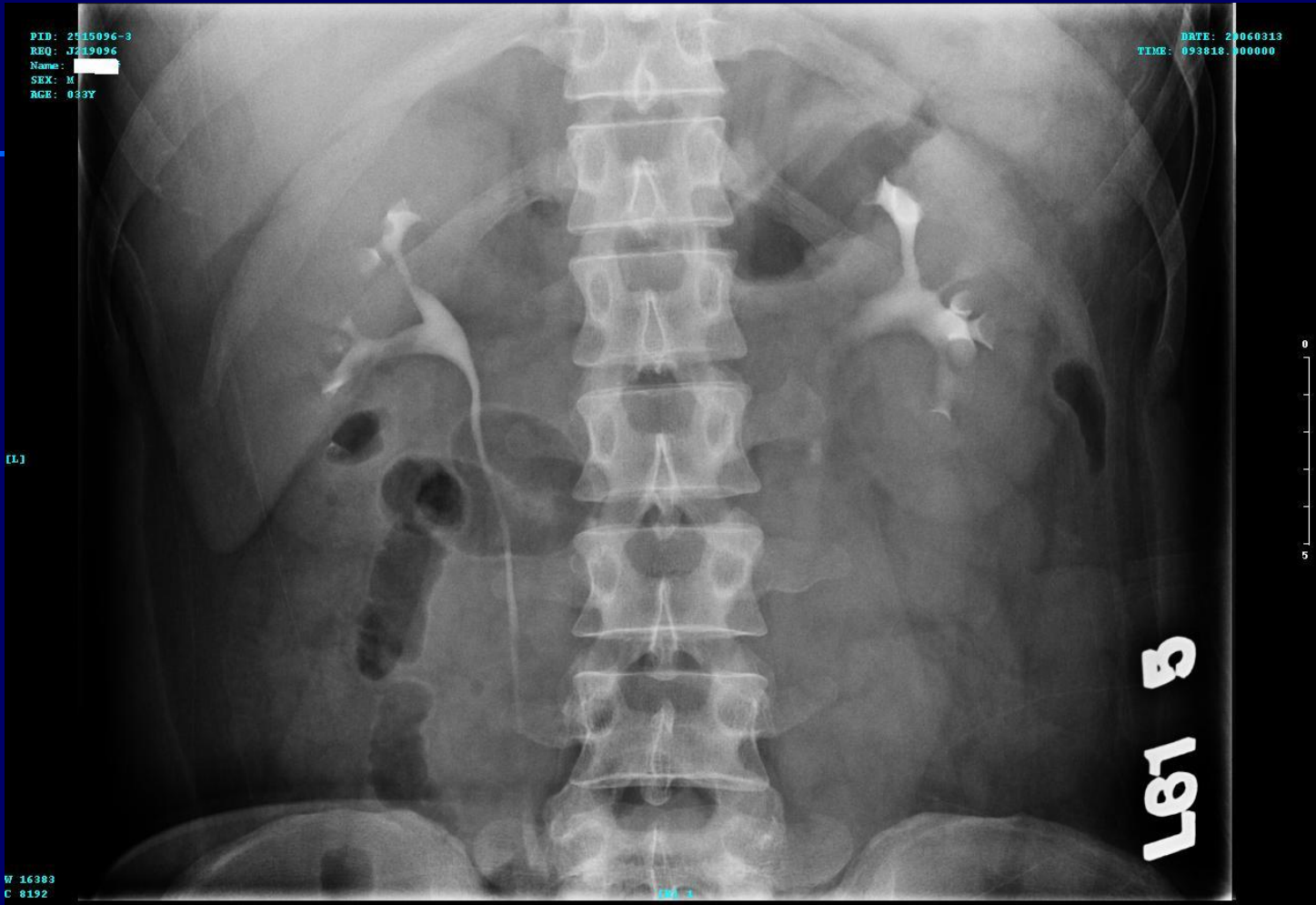
PID: 2515096-3  
REQ: J219096  
Name: [REDACTED]  
SEX: M  
AGE: 083Y

DATE: 20060313  
TIME: 093819.000000

[L]

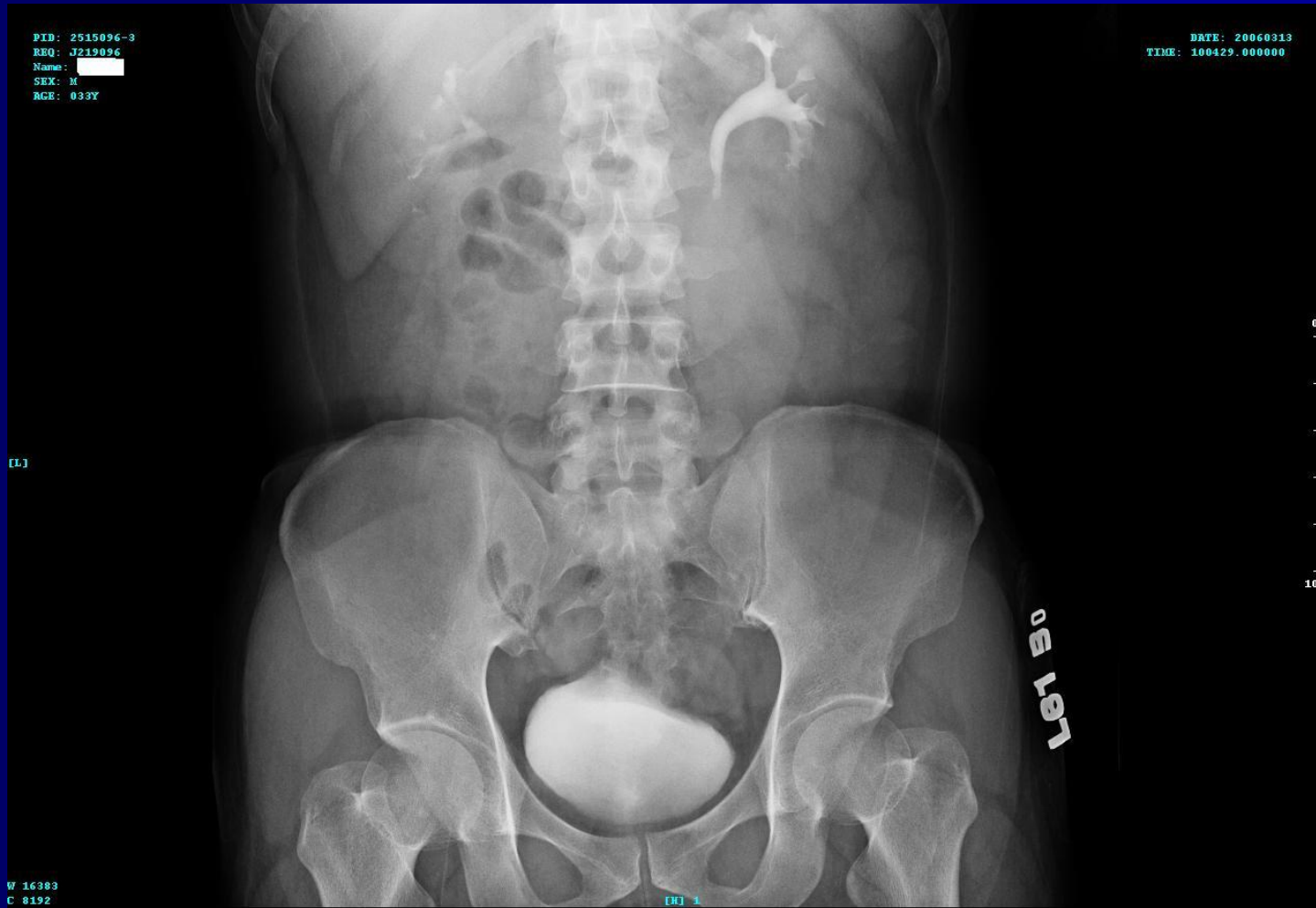
181 B

W 16383  
C 8192

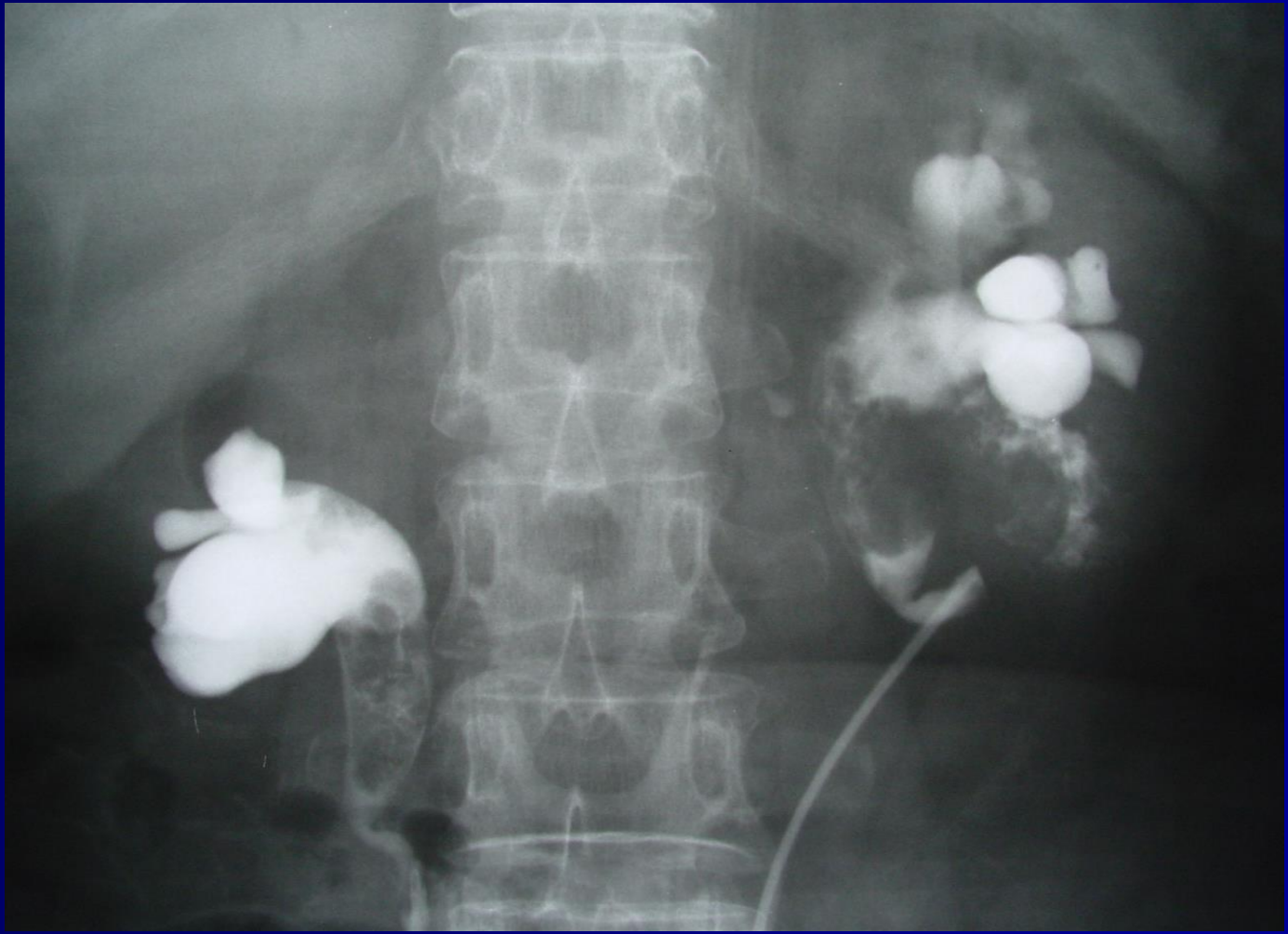




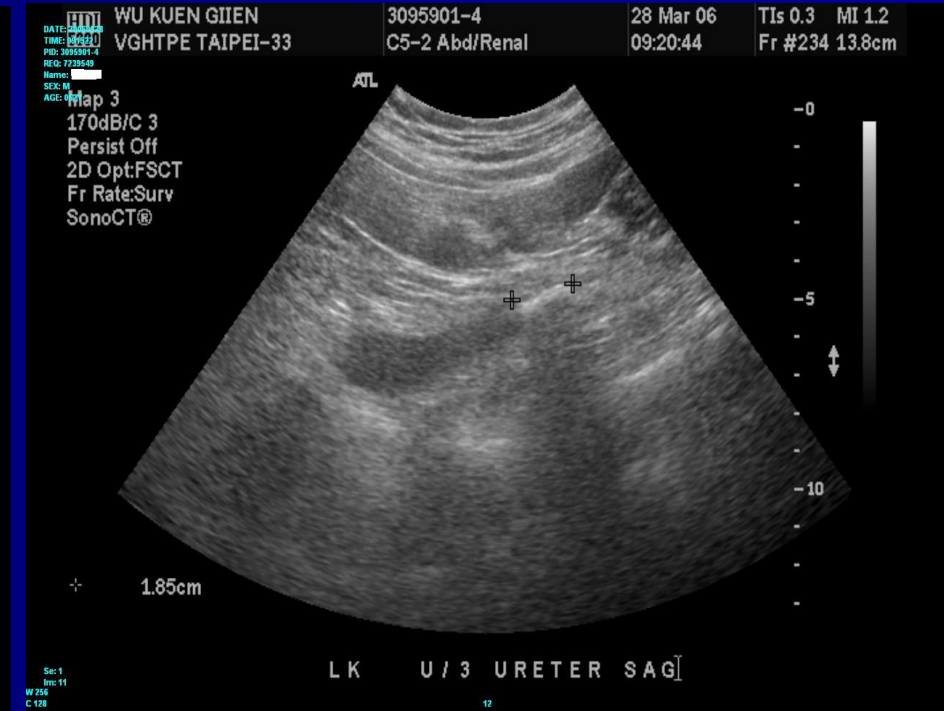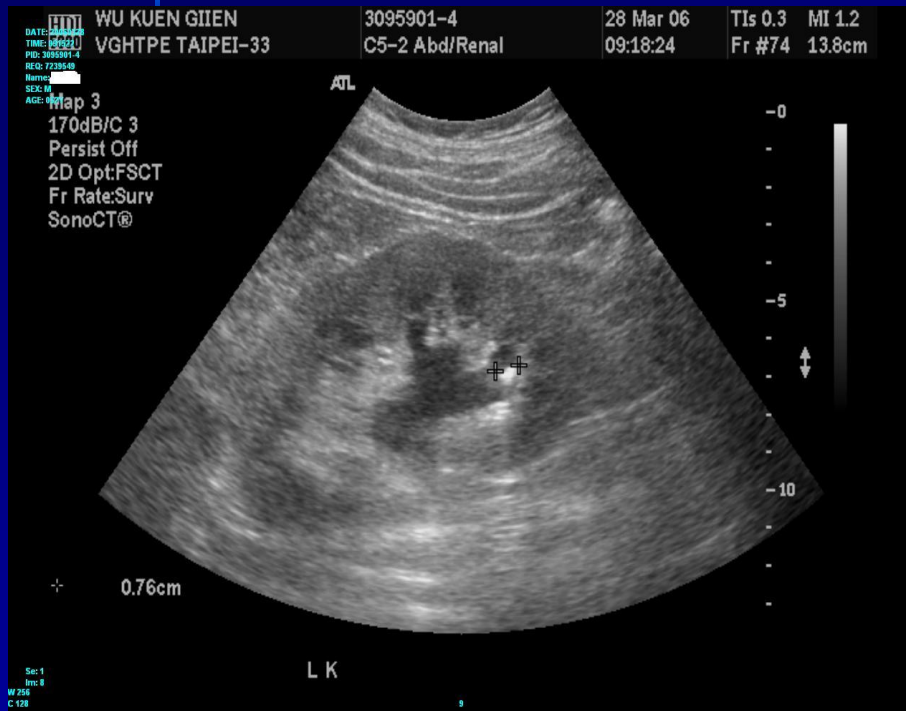
# Intravenous pyelogram F



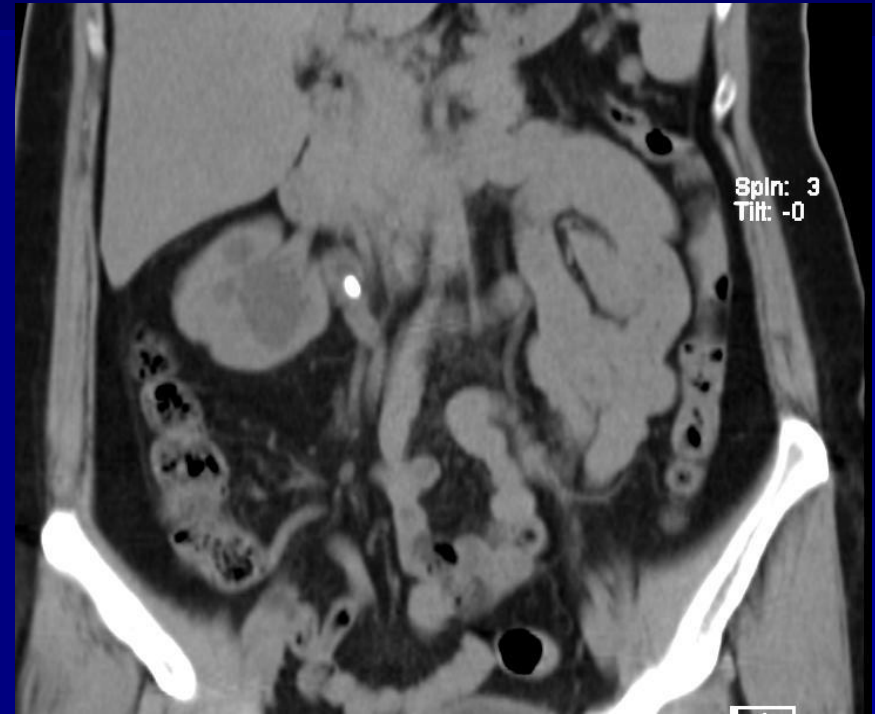
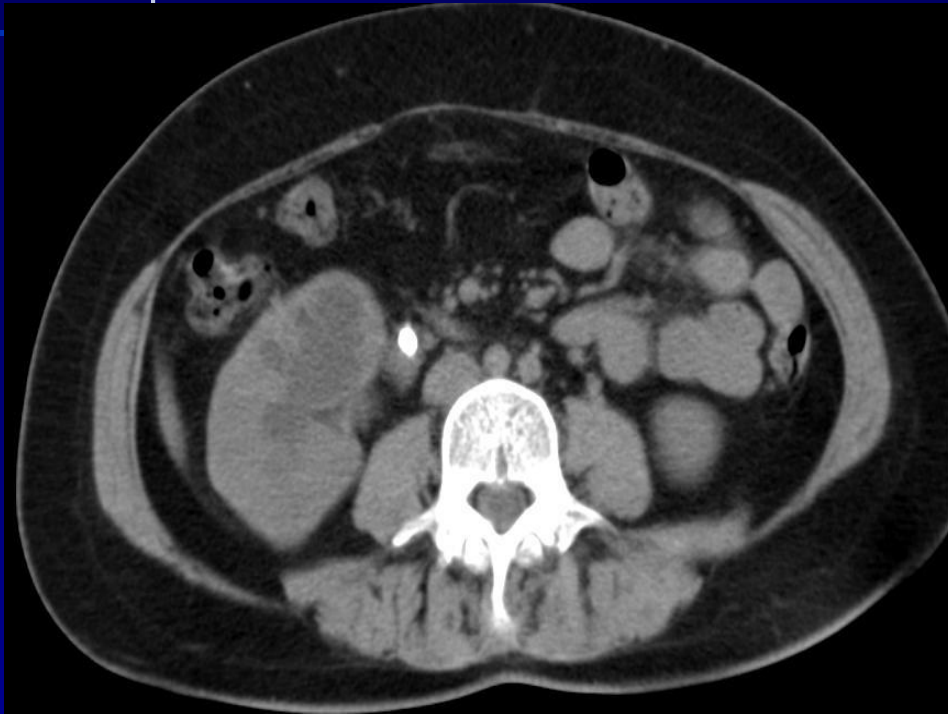# Upper Tract Urothelial Carcinoma

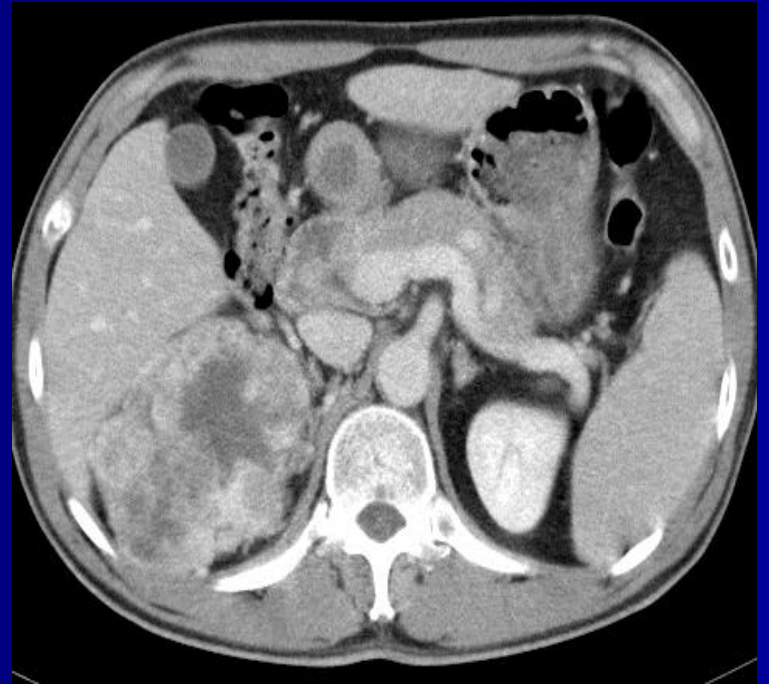
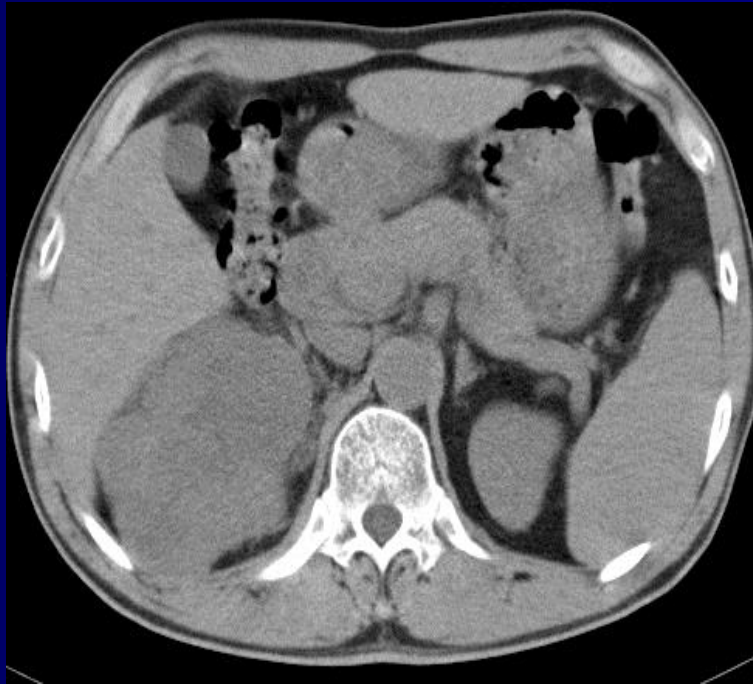


# Sonography of urolithiasis



# CT urogram

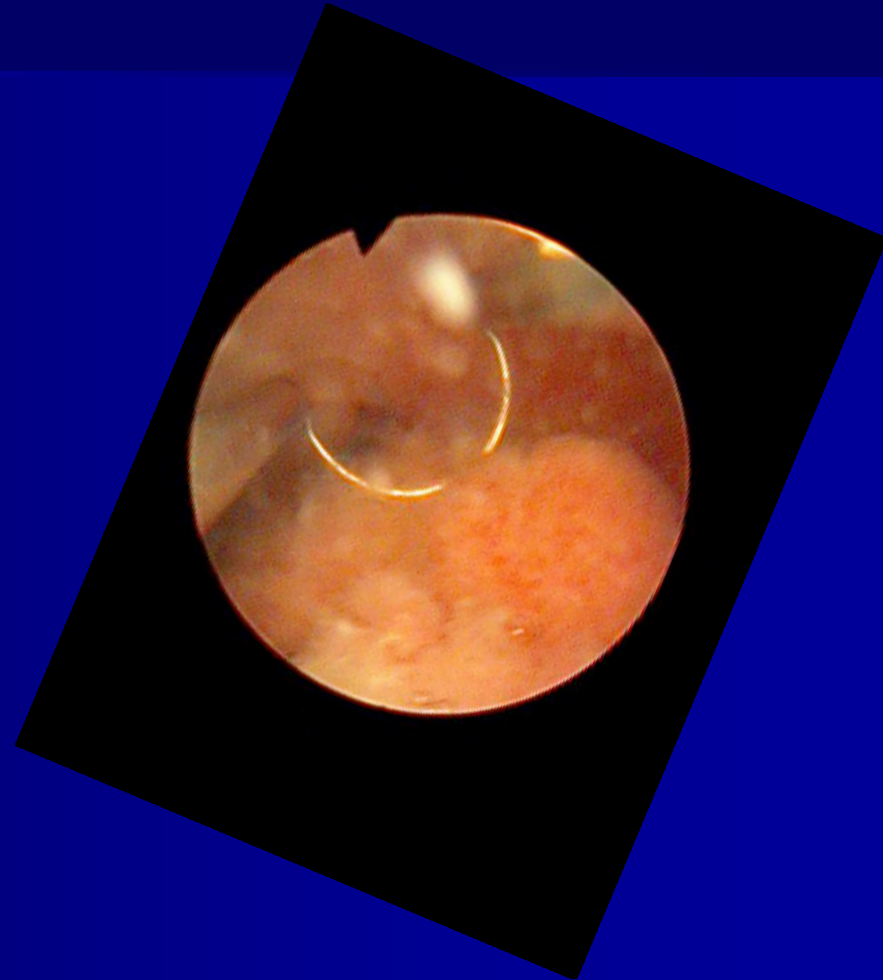
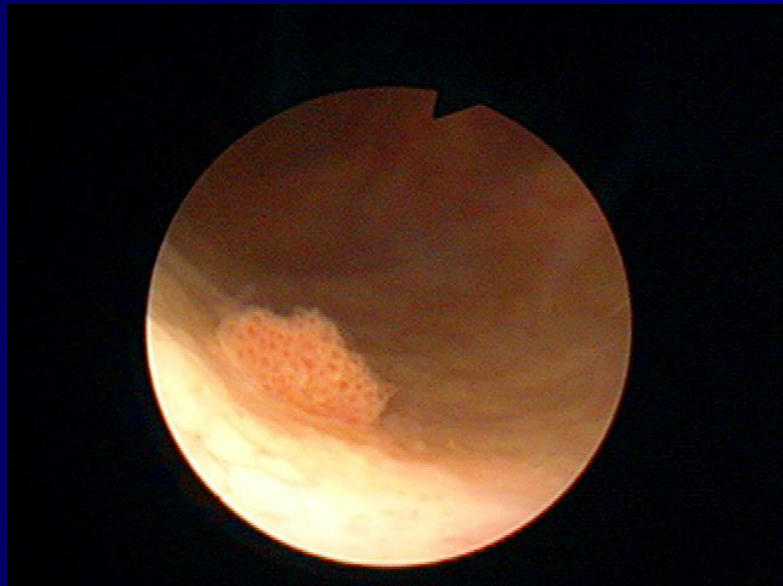






# TURBT

## Transurethral Resection of Bladder Tumor



謝謝聆聽 !!

